


ONTÜSTIK-QAZAQSTAN <b>MEDISINA          AKADEMIASY</b> «Оңтүстік Қазақстан медицина академиясы» АҚ	 SOUTH KAZAKHSTAN <b>MEDICAL          ACADEMY</b> АО «Южно-Казахстанская медицинская академия»
Department of «Topographic anatomy and histology»	52-11
Control and measuring devices	1Page. of 18

## CONTROL AND MEASURING DEVICES

Questions of the program for midterm control 1

**Name of the discipline:** " Respiratory system in normal "

**Discipline code:** NRS 2212

**EP name and code:** 6B10117 – “Dentistry”

**Amount of study hours/credits:** 30/1,0

**Course and semester of study:** 2/4

Compiled by:  senior lecturer Toymbetova K.A.  
 Translated by:  senior lecturer Sartaeva U.S.

1. Morphofunctional characteristics of the respiratory system
2. Classification, sources and course of development
3. Features of the structure of the airways
4. The structure of the nasal cavity
5. The structure of the tracheal wall
6. Bronchial tree
7. Morphofunctional characteristics of the lung.
8. Respiratory lung.
9. The air-blood barrier.
10. Assessment of the role of bronchi and bronchioles in conducting air and providing gas exchange in the lungs.
11. Understanding the mechanisms of respiratory regulation and the bronchial tree's response to various stimuli.
12. Changes in the histology of bronchi and bronchioles in various diseases of the respiratory system, such as asthma, chronic bronchitis, etc.


Head of the Department

 Murzanova D.A.

Protocol No. 11

Date

26.06.2025

ONTÜSTIK-QAZAQSTAN <b>MEDISINA          AKADEMIASY</b> «Оңтүстік Қазақстан медицина академиясы» АҚ	 SOUTH KAZAKHSTAN <b>MEDICAL          ACADEMY</b> АО «Южно-Казахстанская медицинская академия»
Department of «Topographic anatomy and histology»	52-11
Control and measuring devices	1Page. of 18


## Questions of the program for midterm control 2

Compiled by:  senior lecturer Toymbetova K.A.  
 Translated by:  senior lecturer Sartaeva U.S.

1. What is the surfactant-alveolar complex in the lungs?
2. What is the role of the surfactant in the alveolar complex?
3. Describe the structure and composition of the surfactant.
4. What functions does the surfactant perform in the alveolar space?
5. What is the mechanism of action of the surfactant on the surface tension in the alveoli?
6. Which cells synthesize and produce surfactant in the lungs?
7. What changes in the surfactant-alveolar complex can lead to pathological conditions?
8. What research methods allow us to study the surfactant-alveolar complex?
9. What pathologies may be associated with impaired synthesis or function of surfactant?
10. How can understanding the structure and function of the surfactant-alveolar complex be useful for therapists in the diagnosis and treatment of lung diseases?

Head of the Department  Murzanova D.A.

Protocol No.  Date 

ONTÜSTIK-QAZAQSTAN <b>MEDISINA          AKADEMIASY</b> «Оңтүстік Қазақстан медицина академиясы» АҚ	 SOUTH KAZAKHSTAN <b>MEDICAL          ACADEMY</b> АО «Южно-Казахстанская медицинская академия»
Department of «Topographic anatomy and histology»	52-11
Control and measuring devices	1Page. of 18

## CONTROL AND MEASURING DEVICES

Questions of the program for intermediate certification

**Name of the discipline:** " Respiratory system in normal "

**Discipline code:** NRS 2212

**EP name and code:** 6B10117 – “Dentistry”

**Amount of study hours/credits:** 30/1,0

**Course and semester of study:** 2/4

Compiled by:  senior lecturer Toyimbetova K. A.  
 Translated by:  senior lecturer Sartaeva U. S.

<question>The child inhaled a button, which was removed from the right main bronchus with the help of a bronchoscope. Which bronchial epithelium is damaged by a foreign object?

<variant>Single-layer multi-row ciliated

<variant>Multi-layered non-corneating

<variant>Single-layer low-prismatic

<variant>Transitional

<variant>Single-layer flat

<question>The patient was admitted to the department with an attack of suffocation, which is caused by a spasm of the smooth muscles of the respiratory tract.

Identify the sections of the airways that are mainly associated with this attack.

<variant>Small-caliber bronchi

<variant>Medium-caliber bronchi

<variant>Large-caliber bronchi

<variant>Terminal bronchioles

<variant>Respiratory departments

<question>The histological preparation presents an organ whose wall has a mucous, submucosal, fibrous-cartilaginous and adventitial membranes. The epithelium is multi-row ciliated. Mucosal protein glands are located in the submucosal base. Hyaline cartilage forms large plates. Which organ has these morphological features?

<variant>Large bronchus


<variant>Esophagus

<variant>Trachea

<variant>Larynx

<variant>Small bronchus



<p>ONTÜSTIK-QAZAQSTAN MEDISINA AKADEMIASY «Оңтүстік Қазақстан медицина академиясы» АҚ</p>		<p>SOUTH KAZAKHSTAN MEDICAL ACADEMY АО «Южно-Казахстанская медицинская академия»</p>
<p>Department of «Topographic anatomy and histology»</p>		<p>52-11</p>
<p>Control and measuring devices</p>		<p>1Page. of 18</p>

<question>As a result of a nasal injury, the mucous membrane that lines the upper part of the nasal concha is damaged. This led to a violation ...

<variant>perception of odorous substances

<variant>humidification of the air

<variant>secretory activity of goblet cells

<variant>air warming

<variant>warming and humidifying the air

<question>The preparation contains a hollow organ. The mucous membrane is covered with a double-row ciliated epithelium, which turns into a single-row one. The muscular plate of the mucosa is well developed in relation to the thickness of the entire wall. There is no cartilage or glands. Which organ is represented in the preparation?

<variant>Small bronchus

<variant>The middle bronchus

<variant> Large bronchus

<variant>Larynx

<variant>Trachea

<question>The electron micrograph shows structures in the form of open bubbles, the inner surface of which is lined with a single-layer epithelium, which is formed by respiratory and secretory cells. What kind of structures are these?

<variant>Alveoli

<variant>Bronchioles

<variant>Acinuses

<variant>Alveolar passages

<variant>Terminal bronchioles

<question>In the epithelium of the airways there are cells with a domed apical part, on the surface of which microvilli are placed. The synthetic apparatus is well developed in the cell, and secretory granules are in the apical part. What kind of cells are these?

<variant>Clara's Cells

<variant>Goblet - shaped

<variant>Endocrine

<variant>Cells without a border

<variant>Cambial

<question>In the histological preparation of the trachea, low oval or triangular cells are visible as part of the multi-row ciliated epithelium. They do not reach the apical surface of the epithelium with their tip, and mitosis figures are visible in some cells. What function do these cells perform?

<variant>Are a source of regeneration


<variant>They are part of the mucociliary complex

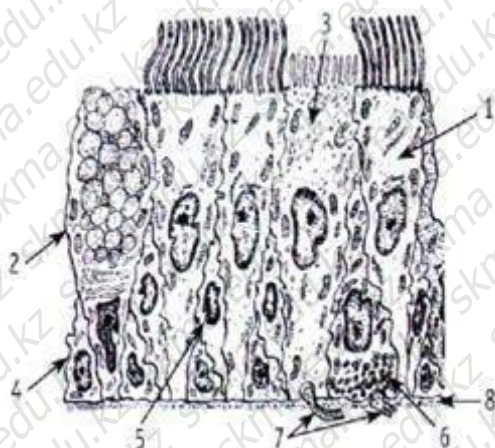
<variant>They secrete mucus

<variant>A surfactant is secreted

<variant>They produce biologically active substances

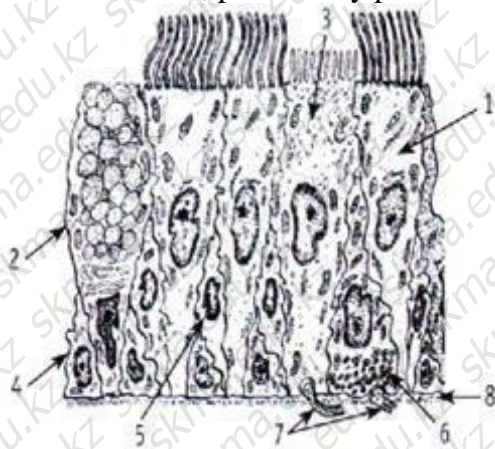
<question>Determine in the picture under which number the cells that perform the function of removing foreign particles from the bronchial cavity are indicated:

<p>ONTÜSTIK-QAZAQSTAN MEDISINA AKADEMIASY «Оңтүстік Қазақстан медицина академиясы» АҚ</p>		<p>SOUTH KAZAKHSTAN MEDICAL ACADEMY АО «Южно-Казахстанская медицинская академия»</p>
<p>Department of «Topographic anatomy and histology»</p>		<p>52-11 1Page. of 18</p>
<p>Control and measuring devices</p>		




- <variant>1
- <variant>2
- <variant>3
- <variant>4
- <variant>5

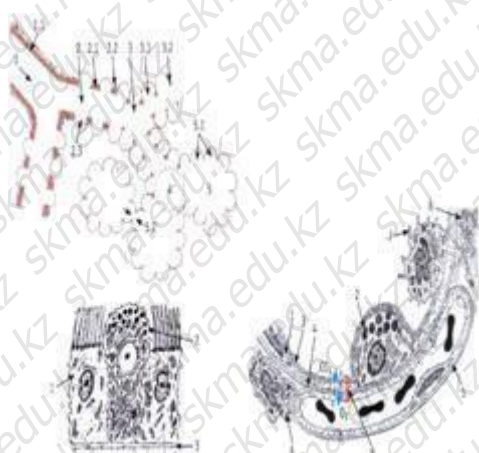<question>Determine in the picture which number indicates the structure in which the bronchial cells are located, presumably performing the function of chemoreceptors:



- <variant>3
- <variant>2
- <variant>4
- <variant>5
- <variant>1

<question>In the picture, determine which number indicates the structure in which the cells containing phagocytic smoke and dust particles are located.

<p>ONTÜSTIK-QAZAQSTAN MEDISINA AKADEMIASY «Онтүстік Қазақстан медицина академиясы» АҚ</p>	 <p>SOUTH KAZAKHSTAN MEDICAL ACADEMY АО «Южно-Казахстанская медицинская академия»</p>
<p>Department of «Topographic anatomy and histology»</p>	<p>52-11</p>
<p>Control and measuring devices</p>	<p>1Page. of 18</p>



- <variant>6
- <variant>7
- <variant>8
- <variant>1
- <variant>2

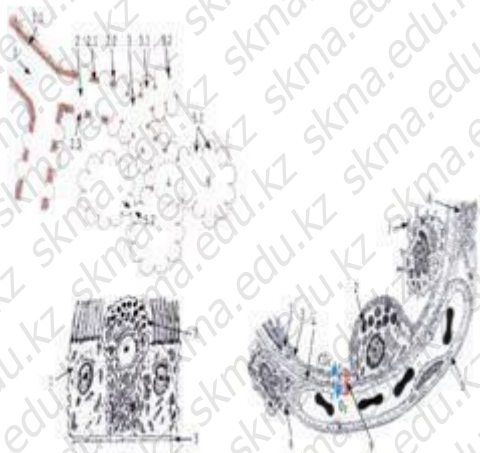<question>In the picture, determine which number indicates the cell containing the enzymes that break down the surfactant:



- <variant>7
- <variant>6
- <variant>5
- <variant>8
- <variant>9

<question>Determine in the picture under which number the structure is indicated, which performs the function of reducing the surface tension of the alveoli, preventing the appearance of edematous fluid in the alveoli:





<variant>3

<variant>4

<variant>5

<variant>6

<variant>7

<question>Which epithelial cells of the mucous membrane of the respiratory tract play the role of single-celled intraepithelial glands?

<variant>goblet-shaped

<variant>ciliated

<variant>edged

<variant>basal

<variant>uncluttered

question>An electronic micrograph consisting of mucous, submucosal, fibrous-cartilaginous and adventitial membranes is given.

The mucous membrane has protein mucous glands, hyaline cartilage forms an open ring. Are these morphological signs of which organ?

<variant>Trachea

<variant>Terminal bronchiola

<variant>The middle bronchus

<variant>Small bronchus

<variant>Larynx

<question>The student conducts a study under a microscope of a histological section of the nasal mucosa. What epithelium is represented by the epithelial plate of the nasal cavity proper?

<variant>multi-row ciliated

<variant>multi-layered flat keratinizing

<variant>multi-layered flat non-horny

<variant>single-layer flat

<variant>loose fibrous connective tissue.


<question>The student conducts a study under a microscope of a histological section of the nasal mucosa and sees a lot of cells covered with cilia. What function do these cilia perform?

<variant>Purification of inhaled air

<variant>Mucus secretion

<variant>Providing a sense of smell

<variant>Increasing the surface for adsorption

<p>ONTÜSTIK-QAZAQSTAN MEDISINA AKADEMIASY «Оңтүстік Қазақстан медицина академиясы» АҚ</p>		<p>SOUTH KAZAKHSTAN MEDICAL ACADEMY АО «Южно-Казахстанская медицинская академия»</p>
<p>Department of «Topographic anatomy and histology»</p>		<p>52-11</p>
<p>Control and measuring devices</p>		<p>1Page. of 18</p>

<variant>Participation in the immune response

<question>The student conducts a study under a microscope of a histological section of the laryngeal mucosa. What kind of tissue is represented by the own plate of the laryngeal mucosa?

<variant>loose fibrous connective tissue

<variant>multi-layered squamous keratinizing epithelium

<variant>hyaline cartilage tissue; <variant>elastic cartilage tissue;

<variant>single-layer squamous epithelium.

<question> The student conducts a study under a microscope of a histological section of the tracheal mucosa. What epithelium is lined with the mucous membrane of the trachea?

<variant> single-layer ciliated

<variant>multi-layered flat keratinizing

<variant>multi-layered flat non-horny

<variant>single-layer flat

<variant> single-layer cubic

<question>Micro-preparations of the airway departments are being investigated. Which sections of the airways are most capable of changing the lumen?

<variant>small-caliber bronchus

<variant>larynx

<variant>trachea

<variant>medium-caliber bronchus

<variant>bronchiola

<question> During the laboratory work, you received a sample of tracheal tissue for examination. Under the microscope, you observe a multi-row ciliated epithelium. What structure do you expect to see under this epithelium?

<variant> Own record

<variant> The protein-mucosal gland

<variant> Muscle plate

<variant> Smooth muscle cell

<variant> The submucosal base

question> The histological micrography shows the alveolus and the alveolar shield (septum).

Identify the cell producing the surfactant:

<variant>type 2 alveolocyte

<variant>type 1 alveolocyte

<variant>goblet cage

<variant>macrophage

<variant>fibroblast

<question> Micrographs of different types of bronchi are given for the study. Determine the type of bronchi where the islands of elastic cartilage meet:

<variant>medium bronchus

<variant>the main bronchus

<variant>small bronchus

<variant>terminal bronchiola


<variant>respiratory bronchiola

<question>When examining a tracheal tissue sample under a microscope, you found the presence of mucous glands. What is the function of these glands in the trachea?

<variant> The production of mucus to moisturize and protect the epithelium

<variant> Production of hormones regulating respiration



<p>ONTÜSTIK-QAZAQSTAN MEDISINA AKADEMIASY «Оңтүстік Қазақстан медицина академиясы» АҚ</p>		<p>SOUTH KAZAKHSTAN MEDICAL ACADEMY АО «Южно-Казахстанская медицинская академия»</p>
<p>Department of «Topographic anatomy and histology»</p>		<p>52-11</p>
<p>Control and measuring devices</p>		<p>1Page. of 18</p>

<variant> Filtration of inhaled air from microorganisms

<variant> Production of lipids to lubricate the respiratory tract

<variant> Regulation of the exchange of gases in the tissue

<question> A patient suffering from chronic cough and shortness of breath underwent bronchoscopy. Microscopic examination of a tissue sample from the bronchial wall revealed a significant number of mucous glands. Where are the end sections of the glands located?

<variant> in the submucosa

<variant> in the mucous membrane

<variant> in the fibrous-cartilaginous membrane

<variant> in an adventitious shell

<variant> in the serous membrane

<question> The student received a sample of a medium-caliber bronchus for examination under a microscope. He notices that the epithelial layer in the bronchus consists of a single-layered epithelium. What is the function of this type of epithelium in the bronchi?

<variant> protection from infections

<variant> cilia movement

<variant> gas exchange

<variant> hormone synthesis

<variant> mucus secretion

<question> The student examines a section of the bronchus and sees that smooth muscle tissue is present in its wall. What function is associated with the presence of smooth muscles in the bronchial wall?

<variant> Regulation of bronchial diameter

<variant> Air filtration

<variant> Mucus production

<variant> Elasticity of the bronchi

<variant> Oxygen transportation

<question> The student studies secretory cells located in the bronchial mucosa. What is the function of these secretory cells?

<variant> Mucus production

<variant> Oxygen transport

<variant> Implementation of gas exchange

<variant> Hormone synthesis

<variant> Antibody production

<question>. When examining a section of the bronchus, the student discovers the presence of cartilage tissue. What role does cartilage play in the bronchial wall?

<variant> Preservation of bronchial shape

<variant> Improved gas exchange

<variant> Ensuring bronchial elasticity

<variant> Hormone production

<variant> Strengthening immunity


<question> The student notices the presence of nerve endings in the bronchial wall on the section of the bronchus. What function is associated with these nerve endings?

<variant> Regulation of contractions of smooth myocytes

<variant> Antibody production

<variant> Ensuring bronchial elasticity

<variant> Increased lung volume

<p>ONTÜSTIK-QAZAQSTAN MEDISINA AKADEMIASY «Оңтүстік Қазақстан медицина академиясы» АҚ</p>		<p>SOUTH KAZAKHSTAN MEDICAL ACADEMY АО «Южно-Казахстанская медицинская академия»</p>
<p>Department of «Topographic anatomy and histology»</p>		<p>52-11 1Page. of 18</p>
<p>Control and measuring devices</p>		

<variant> Air filtration

<question>The students argued about the origin of the lungs. What is the embryonic source of lung development?

<variant> the ventral wall of the primary intestine

<variant> dorsal wall of the primary intestine

<variant> splanchnotome parietal leaflet

<variant> visceral splanchnotome leaflet

<variant> ectoderm

<question> Microscopic examination of a tissue sample from the bronchial wall revealed a significant amount of mucus. Which bronchial epithelial cells produce mucus?

<variant> goblet-shaped

<variant> secretory

<variant> edged

<variant> endocrine

<variant> basal

<question> When examining a tracheal tissue sample under a microscope, you found the presence of a mucous membrane. What is the epithelium of the tracheal mucosa?

<variant> multi-row ciliated

<variant> single row prismatic

<variant> single-layer flat

<variant> multi-layered flat

<variant> single-layer cubic

<question> When examining a tracheal tissue sample under a microscope, you found the presence of mucosal epithelium. What cells are missing in the tracheal epithelium?

<variant> Kupfer cells

<variant> Langerhans cells

<variant> clara cells

<variant> endocrine

<variant> basal

<question> When examining a tracheal tissue sample under a microscope, you did not find smooth myocytes in one of the membranes. In which shell of the trachea are they absent?

<variant> fibrous-cartilaginous

<variant> submucosal basis

<variant> adventitious

<variant> of the mucous membrane

<variant> serous

<question> When examining a section of the bronchus, the student discovers elastic cartilage in the form of islands in its wall. For which bronchus is this pattern characteristic?

<variant> bronchus of the 3rd order

<variant> bronchus of the 2nd order


<variant> bronchus of the 1st order

<variant> small

<variant> of the main

<question> A student examines a section of the bronchus under a microscope and sees that only a mucous membrane and a thin adventitious membrane are present in its wall. For which bronchus is this pattern characteristic?

<variant> small

<p>ONTÜSTIK-QAZAQSTAN MEDISINA AKADEMIASY «Оңтүстік Қазақстан медицина академиясы» АҚ</p>		<p>SOUTH KAZAKHSTAN MEDICAL ACADEMY АО «Южно-Казахстанская медицинская академия»</p>
<p>Department of «Topographic anatomy and histology»</p>		<p>52-11</p>
<p>Control and measuring devices</p>		<p>1Page. of 18</p>

<variant> of the main

<variant> 3 orders of magnitude

<variant> of the 1st order

<variant> 2 orders of magnitude

<question> When examining the cross-section of different sections of the airways, the student discovers that goblet cells in the epithelium are replaced by Clara cells. Which department did the incision go through?

<variant> terminal bronchiola

<variant> small-caliber bronchus

<variant> medium-caliber bronchus

<variant> the main bronchus

<variant> trachea

<question> Microscopic examination of the histopreparation of pulmonary acinus shows that the walls of the alveolar passages consist of a single-layer epithelium, and capillaries are located in their lumen. What type of epithelium prevails in this histopreparation?

<variant> Flat

<variant> Cubic

<variant> Cylindrical

<variant> Prismatic

<variant> Transitional

<question> When examining the histopreparation of the lung, you found that its structure contains cells containing lamellar bodies of phospholipids. What are these cells called?

<variant> Type II alveolocytes

<variant> Type I alveolocytes

<variant> Endothelial cells

<variant> Basal cells

<variant> Clara Cells

<question> During the study of the histopreparation of the lung, you found that its walls consist of epithelial cells with pronounced microvilli. What function do these microvilli have?

<variant> Increasing the gas exchange surface

<variant> Oxygen absorption

<variant> Mucus secretion

<variant> Air filtration

<variant> Surfactant production

<question> In the histopreparation of the lung, you observe round or oval cavities surrounded by a single-layer epithelium. These structures are the final extensions of the alveolar passages. What are they called?

<variant> Alveolar sacs

<variant> Alveolar macrophages

<variant> Bronchioles

<variant> Alveolar capillaries


<variant> Alveoli

<question> In the histopreparation of the lung, you observe epithelial cells with flat nuclei adjacent to the thin walls of the alveolar sacs. Which cells are represented in this histopreparation?

<variant> Type I alveolocytes

<variant> Macrophages



<p>ONTÜSTIK-QAZAQSTAN MEDISINA AKADEMIASY «Оңтүстік Қазақстан медицина академиясы» АҚ</p>		<p>SOUTH KAZAKHSTAN MEDICAL ACADEMY АО «Южно-Казахстанская медицинская академия»</p>
<p>Department of «Topographic anatomy and histology»</p>		<p>52-11</p>
<p>Control and measuring devices</p>		<p>1Page. of 18</p>

<variant> Endothelial cells

<variant> Type II alveolocytes

<variant> Basal cells

<question> Microscopic examination of the histopreparation of the lung shows that its structure consists of alveolar sacs, and their walls are thin and consist of a single-layer epithelium surrounded by capillaries. What process is carried out in this structure?

<variant> Gas diffusion

<variant> Mucus secretion

<variant> Phagocytosis

<variant> Surfactant products

<variant> Cell proliferation

<question> In the histopreparation of the lung, you observe that its structure is represented by alveolar sacs surrounded by a network of capillaries. What important property of the alveolar walls ensures the efficiency of gas exchange?

<variant> High permeability to gases

<variant> The presence of cilia on cells

<variant> Wall thickness

<variant> The presence of macrophages

<variant> Mucus production

<question> When microscopically examining the histopreparation of the lung, you can see that cells containing lipid granules are present in its structure. What is the function associated with these cells?

<variant> Surfactant secretion

<variant> Mucus production

<variant> Phagocytosis

<variant> Immune protection

<variant> Gas transport

<question> When examining the histopreparation of the lung, you found that its structure consists of alveolar sacs surrounded by capillaries, and between them there is an alveolar interstitium. What function characterizes the alveolar interstitium?

<variant> Maintaining the structure

<variant> Air filtration

<variant> Mucus production

<variant> Surfactant production

<variant> Phagocytosis

<question> In the histopreparation of the lung, you observe structures represented by bubbles with thin walls surrounded by a network of capillaries. What are these structures called?

<variant> Alveoli

<variant> Alveolar sacs


<variant> Alveolar capillaries

<variant> Alveolar macrophages

<variant> Alveolar passages

<question> Microscopic examination of the histopreparation of lung tissue reveals characteristic structures resembling dense balls or bubbles distributed over the entire surface of the alveolar walls. What structure does this description correspond to?

<variant> Alveoli

<p>ONTÜSTIK-QAZAQSTAN MEDISINA AKADEMIASY «Оңтүстік Қазақстан медицина академиясы» АҚ</p>		<p>SOUTH KAZAKHSTAN MEDICAL ACADEMY АО «Южно-Казахстанская медицинская академия»</p>
<p>Department of «Topographic anatomy and histology»</p>		<p>52-11</p>
<p>Control and measuring devices</p>		<p>1Page. of 18</p>

<variant> Alveolar sacs

<variant> Alveolar capillaries

<variant> Alveolar macrophages

<variant> Alveolar passages

<question> In the histopreparation of lung tissue, you notice cells with a cubic shape, distributed over the entire surface of the alveolar walls, are key in the process of secretion of a specific substance that reduces surface tension. Which cells does this description correspond to?

<variant> Type II alveolocytes

<variant> Type I alveolocytes

<variant> Endothelial cells

<variant> Alveolar macrophages

<variant> Fibroblasts

<question> When studying histopreparation of lung tissue, you observe cells with a flat shape forming a thin layer that makes up most of the alveolar walls. These cells are key to the gas exchange process in the lungs. Which cells does this description correspond to?

<variant> Type I alveolocytes

<variant> Type II alveolocytes

<variant> Fibroblasts

<variant> Capillary endothelial cells

<variant> Alveolar macrophages

<question> In the histopreparation of lung tissue, you find round structures distributed along the alveolar walls and externally resembling small bubbles. These structures contain an important substance that ensures the stability of the alveolar bladders to stick together during exhalation. What structures does this description correspond to?

<variant> Type II alveolocytes

<variant> Type I alveolocytes

<variant> Fibroblasts

<variant> Alveolar macrophages

<variant> Elastic fibers

<question> When examining a histopreparation of lung tissue, you find cells distributed in the alveolar interstitium. These cells perform an important function in maintaining homeostasis and protecting the tissue microenvironment of the lung. Which cells does this description correspond to?

<variant> Alveolar macrophages

<variant> Capillary endothelial cells

<variant> Fibroblasts

<variant> Type II alveolocytes

<variant> Type I alveolocytes

<question> During the study of histopreparations of different departments of the airways, you find that the mucous membrane of one organ in different areas is lined with both a single-layer ciliated epithelium and a multilayer flat non-corneating one. Which organ are you examining?


<variant> Larynx

<variant> Trachea

<variant> The main bronchus

<variant> The middle bronchus

<variant> Easy

ONTÜSTIK-QAZAQSTAN <b>MEDISINA          AKADEMIASY</b> «Оңтүстік Қазақстан медицина академиясы» АҚ	 SOUTH KAZAKHSTAN <b>MEDICAL          ACADEMY</b> АО «Южно-Казахстанская медицинская академия»
Department of «Topographic anatomy and histology»	52-11
Control and measuring devices	1Page. of 18

<question> During the study of the bronchial histopreparation, you find that one of the structures prevails in the bronchial wall. Which of the listed structures prevails in the wall?

- <variant> muscle plate
- <variant> epithelial plate
- <variant> fibrous cartilage
- <variant> submucosal base
- <variant> own record

<question> When examining a microscopic preparation, the presence of cartilaginous rings in the bronchial wall was found. What is the function of cartilage rings in bronchi?

- <variant> Maintenance of bronchial lumen
- <variant> Participation in the breathing process
- <variant> Providing elasticity
- <variant> Filtration of inhaled air
- <variant> Mucus production

<question> Microscopic analysis of the small-caliber wall of the bronchus revealed the presence of smooth myocytes. What processes can be controlled by smooth myocytes in the bronchial wall?

- <variant> Expansion and narrowing of the bronchial lumen
- <variant> Maintaining the structure of the epithelium
- <variant> Active gas transport
- <variant> Production of mucus for protection
- <variant> Participation in active transport of substances

<question> You have been provided with a histopreparation for analysis. The slide shows: a multilayer flat keratinizing epithelium and a connective tissue layer with hair follicles and sebaceous glands. Which section of the airways do you see on this histopreparation?

- <variant> vestibule of the nasal cavity
- <variant> the actual nasal cavity
- <variant> nasopharynx
- <variant> oropharynx
- <variant> larynx

Head of the Department


Murzanova D.A.

Protocol No. 11

Date

26.06.2025



ONTÜSTIK-QAZAQSTAN <b>MEDISINA          AKADEMIASY</b> «Оңтүстік Қазақстан медицина академиясы» АҚ	 SOUTH KAZAKHSTAN <b>MEDICAL          ACADEMY</b> АО «Южно-Казахстанская медицинская академия»
Department of «Topographic anatomy and histology»	52-11
Control and measuring devices	1Page. of 18

## CONTROL AND MEASURING DEVICES

1 (2) technical specifications and test tasks for intermediate control or intermediate certification

**Name of the discipline:** " Respiratory system in normal "

**Discipline code:** NRS 2212


**EP name and code:** 6B10117 – “Dentistry”

**Amount of study hours/credits:** 30/1,0

**Course and semester of study:** 2/4

Compiled by:  senior lecturer Toymbetova K.A.  
 Translated by:  senior lecturer Sartaeva U.S.

1. Morphofunctional characteristics of the respiratory system
2. Classification, sources and course of development
3. Features of the structure of the airways
4. The structure of the nasal cavity
5. The structure of the tracheal wall
6. Bronchial tree
7. Morphofunctional characteristics of the lung.
8. Respiratory lung.
9. The air-blood barrier.
10. Assessment of the role of bronchi and bronchioles in conducting air and providing gas exchange in the lungs.
11. Understanding the mechanisms of respiratory regulation and the bronchial tree's response to various stimuli.
12. Changes in the histology of bronchi and bronchioles in various diseases of the respiratory system, such as asthma, chronic bronchitis, etc.
13. What is the surfactant-alveolar complex in the lungs?  
 What is the role of the surfactant in the alveolar complex?

ONTÜSTIK-QAZAQSTAN <b>MEDISINA          AKADEMIASY</b> «Оңтүстік Қазақстан медицина академиясы» АҚ	 SOUTH KAZAKHSTAN <b>MEDICAL          ACADEMY</b> АО «Южно-Казахстанская медицинская академия»
Department of «Topographic anatomy and histology»	52-11
Control and measuring devices	1Page. of 18


14. Describe the structure and composition of the surfactant.
15. What functions does the surfactant perform in the alveolar space?
16. What is the mechanism of action of the surfactant on the surface tension in the alveoli?
17. Which cells synthesize and produce surfactant in the lungs?
18. What changes in the surfactant-alveolar complex can lead to pathological conditions?
19. What research methods allow us to study the surfactant-alveolar complex?
20. What pathologies may be associated with impaired synthesis or function of surfactant?
21. How can understanding the structure and function of the surfactant-alveolar complex be useful for therapists in the diagnosis and treatment of lung diseases?

Head of the Department

Murzanova D.A.

Protocol No.

Date

ONTÜSTIK-QAZAQSTAN <b>MEDISINA          AKADEMIASY</b> «Оңтүстік Қазақстан медицина академиясы» АҚ	 SOUTH KAZAKHSTAN <b>MEDICAL          ACADEMY</b> АО «Южно-Казахстанская медицинская академия»
Department of «Topographic anatomy and histology»	52-11
Control and measuring devices	1Page. of 18

## CONTROL AND MEASURING DEVICES

List of practical skills in the discipline

**Name of the discipline:** " Respiratory system in normal "

**Discipline code:** NRS 2212

**EP name and code:** 6B10117 – “Dentistry”


**Amount of study hours/credits:** 30/1,0

**Course and semester of study:** 2/4

Compiled by:  senior lecturer Toyymbetova K.A.  
 Translated by:  senior lecturer Sartaeva U.S.

### List of permanent histological micropreparations

1. Describe the histopreparation "nasal mucosa".
2. Describe the histopreparation of the trachea.
3. Determine the type of veins in the lower extremities.
4. Describe the structure of the terminal bronchiole.
5. Describe the electronogram of the alveoli and the interalveolar septum.
6. Describe the histopreparation "lung with visceral pleura".
7. Describe the histopreparation "intra-pulmonary airways".
8. Describe the histopreparation "small bronchus".
9. Describe the histopreparation "lung with lymphoid tissue".
10. Describe the electronic micrography of the bronchial epithelium.
11. Describe the histostructures involved in the aerogematic barrier.
12. Determine the type of veins

Head of the Department  Murzanova D.A.  
 Protocol No. 11 Date 16.06.2025



